

# Subcutaneously Placed Breast Implants after a Skin-Sparing Mastectomy: Do We Always Need ADM?

Apresh Singla, MBBS, MSc\*†  
Animesh Singla, MBBS†  
Eric Lai, MBBS†  
David Caminer, FRACS\*

**Background:** Immediate breast reconstruction is an acceptable treatment option after mastectomy for prophylaxis of early breast cancer. Different options exist for implant placement, incision technique, patient suitability, and institutional experience. This article is a case series exploring the feasibility and outcomes of patients undergoing immediate breast reconstruction using skin-sparing mastectomy without mesh or acellular dermal matrix (ADM) and with a vertical inframammary incision.

**Methods:** A single-institution retrospective analysis was performed for all patients who underwent immediate single-stage reconstruction with subcutaneous silicon implants without ADM between 2009 and 2014 inclusive. Patient, operative and treatment variables were extracted. All patients with viable mastectomy skin flaps intraoperatively and at least 5 mm of subcutaneous tissue were eligible except for patients who were deemed too slim by the senior surgeon preoperatively and thus at risk of implant visibility or skin rippling.

**Results:** There were 26 patients (bilateral  $n = 12$  and unilateral  $n = 14$ ) eligible for analysis, with a median long-term follow-up of 51.5 months. The majority of complications were classified as minor affecting 46.2% of the cohort ( $n = 12$ ). There were 20 episodes of complications overall. The most frequent episodes were contour defects ( $x = 5$ ), minor seroma ( $x = 4$ ), and malrotation and minor infection ( $x = 3$ ). There was 1 episode of capsular contracture.

**Conclusion:** Skin-sparing mastectomy with immediate subcutaneous silicon implant reconstruction with a vertical incision and without the need for mesh or ADM is an acceptable and safe treatment option. Accurate patient selection and skin flap viability is the key to achieving optimal outcomes with this approach. (*Plast Reconstr Surg Glob Open* 2017;5:e1371; doi: 10.1097/GOX.0000000000001371; Published online 12 July 2017.)

## INTRODUCTION

Skin-sparing mastectomy (SSM) has proven to be an effective treatment for prophylactic mastectomy, and there is a growing consensus of its role in appropriately selected patients with early breast cancer.<sup>1,2</sup> Options for reconstruction include the use of implants placed in the subpectoral

or subcutaneous pocket as either a single-stage or multi-stage procedure. Single-stage direct-to-implant-based reconstruction has been shown to reduce operating time, cost, and morbidity compared with the 2-step expander/implant reconstruction.<sup>3,4</sup> Immediate reconstruction also results in improved patient satisfaction and better psychological sequelae.<sup>5,6</sup>

The use of acellular dermal matrix (ADM) further allowed for immediate single-stage reconstruction as it offered an additional layer of coverage between skin and implant and also shorted the expander/implant reconstruction process when used in the 2-step method of reconstruction. However, ADM is not without its drawbacks and has been shown to have higher rates of seroma, infection rates, mastectomy flap necrosis compared with the non-ADM reconstruction.<sup>7</sup>

Earlier studies evaluating subcutaneous placement of implants suggested that it was inferior to subpectoral

From the \*Department of Plastic Surgery, St Vincent's Hospital, Sydney, NSW, Australia; and †University of New South Wales, Sydney, NSW, Australia.

The research was approved by the local ethics committee. This research was conducted in accordance with the Declaration of Helsinki.

Received for publication November 20, 2016; accepted April 20, 2017.

Copyright © 2017 The Authors. Published by Wolters Kluwer Health, Inc. on behalf of The American Society of Plastic Surgeons. This is an open-access article distributed under the terms of the Creative Commons Attribution-Non Commercial-No Derivatives License 4.0 (CCBY-NC-ND), where it is permissible to download and share the work provided it is properly cited. The work cannot be changed in any way or used commercially without permission from the journal.

DOI: 10.1097/GOX.0000000000001371

**Disclosure:** The authors have no financial interest to declare in relation to the content of this article. The Article Processing Charge was paid for by the authors.

placement. Higher rates of contractures, implant loss, and displacement were often sited, particularly in irradiated breasts.<sup>8,9</sup> Nevertheless, the benefits of subcutaneous implant placement include the ease of dissection and reduced pain, no hyper animation deformity, predictable sizing, and better symmetry.<sup>10</sup> There has been a recent renewed interest in subcutaneous implant placement, which has been made possible by improvement in and assessment of skin flap quality and evolution of techniques.<sup>11-13</sup>

Another important consideration in reconstruction is the choice of incision. The incisions typically used in SSM include radial, transverse periareolar, lateral, inferolateral, double concentric periareolar, vertical infraareolar, or inframammary approaches.<sup>14,15</sup> There is evidence that the incision technique can influence blood circulation over the superficial skin.<sup>16,17</sup> Jensen et al.<sup>18</sup> described the concept of “degrees of perfusion” of the nipple-areolar complex as key in determining rates of nipple necrosis. The choice of incision type in combination with other patient factors including body mass index, smoking, and radiotherapy affect the rate of skin necrosis and overall complications. Vertical infraareolar incisions have anatomical merit in optimizing perfusion around nipple areolar complex by preserving the superior and inferior blood vessel supply.

We chose to take the next logical step to assess as a case series the feasibility of subcutaneous single-stage implant-based reconstruction without the use of ADM. The justification for this approach is to avoid the morbidity and animation deformity associated with subpectoral placement of implants and to improve the cost-effectiveness by eliminating a second-stage operation and ADM.

This report presents a single-institution experience with SSM using a vertical infraareolar incision and single-stage reconstruction using subcutaneous silicone implants without ADM. Indications, complications, and outcomes of this technique are explored.

## METHODS

A single-institution retrospective analysis was performed for all patients who underwent immediate subcutaneous single-stage reconstruction after SSM between 2009 and 2014 inclusive. Patient, operative and treatment variables were extracted. Postoperative episodes of minor infection, major infection, malrotation, contractures, hematoma, seroma, skin necrosis, and implant loss from any cause were recorded. Some patients had more than 1 complication, and these were recorded as separate events. Breast ptosis was analyzed preoperatively using the Regnault Classification.

Patient selection for this technique was based mainly on intraoperative assessment of at least 5 mm of subcutaneous fat with the skin envelope and the good viability of the skin flap. The suitability for subcutaneous placement of implants was subsequently decided by the senior author. The only exclusion criterion was if the patient was deemed too slim by the senior surgeon preoperatively and thus would benefit from ADM coverage to avoid implant visibility and rippling.

The vertical inframammary skin incision is planned in conjunction with a specialist general surgeon and a decision is made whether to retain or resect the nipple. After the SSM, the patient is repped and draped. The breast cavity is irrigated with betadine/antibiotic solution and the skin flaps investigated for viability. If there is at least 5 mm of subcutaneous tissue and healthy vascularized skin flap, the decision is made to place the implant in the subcutaneous pocket without ADM. An external drain is inserted and secured to the skin and breast cavity irrigated once again with betadine/antibiotic solution. The gloves are changed before insertion of the cohesive silicone gel implant. The lateral pocket is closed with a barb suture to minimize the chance for malrotation. Skin sutures are used to close the vertical inframammary incision and sterile dressings applied.

Minor infection was defined as superficial infection necessitating oral antibiotics as an outpatient only. Major infection was defined as requiring intravenous antibiotics and/or hospital admission. Minor seroma or hematoma were defined as those managed conservatively or with percutaneous drainage. Major seroma or hematoma were defined as those necessitating hospital admission for reoperation.

Malrotation was defined as any rotation of the implant postoperatively that makes the breast look misshapen. The complication was detected at clinical follow-up visits postoperatively by the senior surgeon. Although it can be difficult to detect clinically, this was not the case in our patient case series who all underwent SSM and subcutaneous placement of the implant making any malrotation obvious.

The degree of contracture was based on the 4-grade Baker scale. Minor skin necrosis was defined as those managed conservatively. All complications were assessed by the senior operating surgeon.

The senior surgeons' practice is to use Allergan Style 410 anatomical implants for all the cases.

These are highly cohesive anatomically shaped silicon-filled implants with a textured surface.

A chi-squared analysis was undertaken of overall and individual postoperative complications with patients, pathology, and treatment factors. All statistical analysis was done using SPSS v17.0<sup>19</sup> statistical analysis software (IBM).

## RESULTS

Overall 26 patients (n = 26) were identified who had undergone immediate reconstruction with subcutaneous implant after SSM with a vertical inframammary incision. The median age of the patients was 51 years. The median duration of follow-up was 51.5 months and ranged from a minimum of 29 months to a maximum of 81 months.

When analyzing breast ptosis preoperatively, 15.4% (n = 4) had grade 1 ptosis and 84.6% (n = 22) had grade 2 or greater ptosis. When looking at smoking status, 88.5% (n = 23) of patients were nonsmokers.

A total of 46.2% (n = 12) underwent bilateral reconstruction. The final pathology was benign in 30.8% (n = 8), ductal carcinoma in situ in 38.5% (n = 10), and invasive cancer in 30.8% (n = 8). The reason for benign

pathology was because some patients had prophylactic SSM for BRCA1/BRCA2 gene mutations. When looking at confounding oncological factors, 30.8% (n = 8) of women underwent chemotherapy, 19.2% (n = 5) underwent radiotherapy (postoperatively), and 7.7% (n = 2) underwent hormonal therapy. The median implant size used was 445 g and ranged from 225 to 690 g.

The overall complication rate was 46.2% (n = 12) with 20 episodes recorded in total. The majority of complications were minor with only 1 episode of a major infection. The breakdown by complication and as a percentage of the total cohort is shown in Table 1. There was 1 instance of capsular contracture necessitating replacement of implant over the follow-up period.

On statistical analysis using Fisher's exact test of numerous patient pathology and treatment factors, none were shown to predict increased complication rates overall. On subanalysis of individual complications in the same fashion, no factors were shown to predict increased risk of specific complications (Figs. 1, 2).

**Table 1. Type of complications**

Type of complication	Episodes (x)	%
Minor infection	3	11.5
Major infection	1	3.8
Malrotation	3	11.5
Contracture	1	3.8
Minor hematoma	1	3.8
Minor seroma	4	15.3
Skin necrosis	0	0
Scar revision	2	7.7
Contour defect	5	19.2
Loss of implant	0	0
Total	20	73

## DISCUSSION

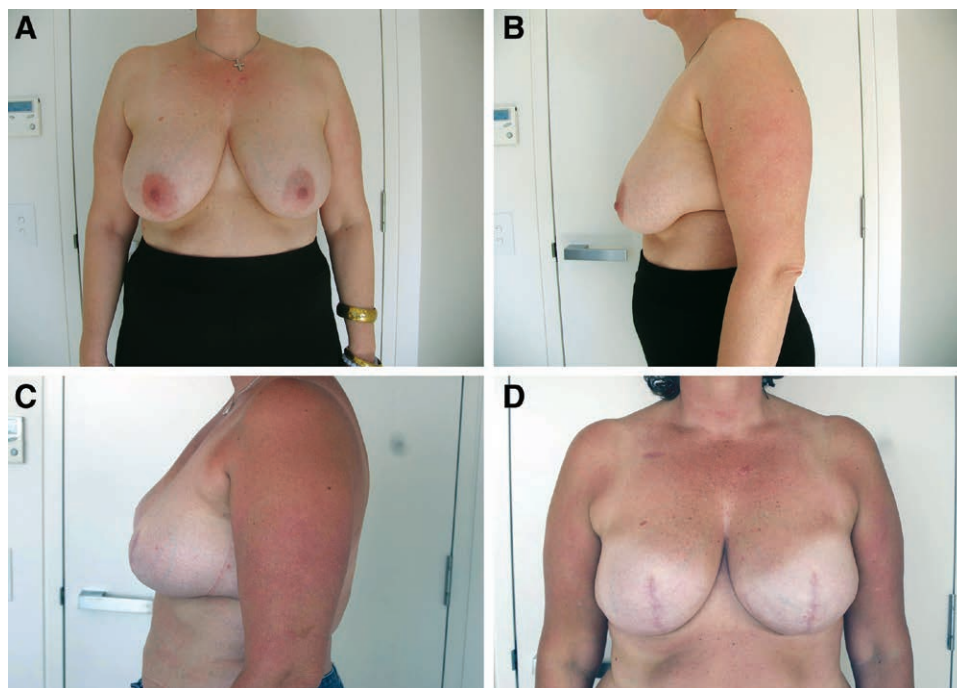
This article reports experience with subcutaneous implants and immediate reconstructive surgery after SSM with a vertical inframammary incision. The positive psychological impact with immediate breast reconstruction after mastectomy has been well documented.<sup>20,21</sup>

### Contractures and Skin Necrosis

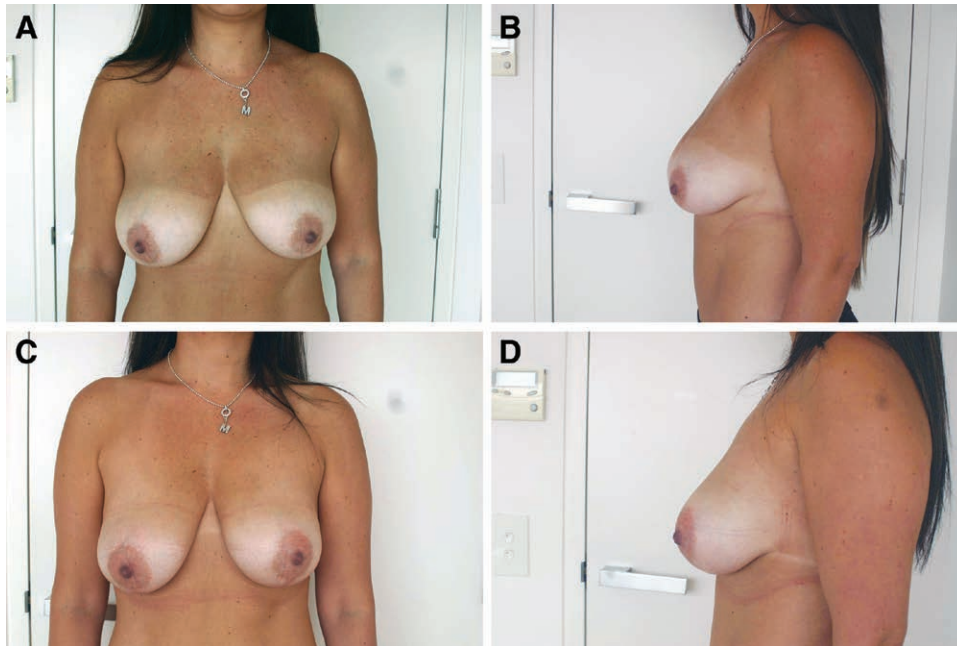
Historical reports have found much more favorable outcomes for subpectoral versus subcutaneous implants.<sup>8</sup> Our complication rates are much lower than in previously documented case series. In particular, the capsular contracture rate was only 3.8% over a median follow-up of 51.5 months. Another previous case series demonstrated a cumulative contracture rate of greater than 20% with subcutaneously placed implants.<sup>10</sup> In recent publications evaluating subcutaneous placed implants with either ADM or titanium-coated mesh, Bernini et al.<sup>11</sup> reported a significantly superior outcome in terms of contractures and aesthetics with subcutaneous versus subpectoral placement of implants and showed zero grade III–IV contractures. They hypothesized that subcutaneous placement avoids any mechanical stress over the implant and its capsule in contrast to the subpectoral placement.

Additionally, there is good evidence from cosmetic breast augmentation that the use of a textured implant in a subglandular position is associated with a reduced incidence of capsular contracture compared with smooth implants.<sup>22</sup> Although our study focuses on reconstructive rather than cosmetic breast implants, it may further explain the low rates of capsular contracture in our patient cohort.

The senior surgeons' experience in this report is that subcutaneous placement is technically easier and more



**Fig. 1.** Preoperative (A and B) and postoperative (C and D) photographs in a patient who underwent bilateral prophylactic mastectomy and immediate reconstruction with an Allergan 410Fx implant.



**Fig. 2.** Preoperative (A and B) and postoperative (C and D) photographs in a patient who underwent unilateral mastectomy (left-sided) for invasive cancer and immediate reconstruction with an Allergan 410 Fx implant.

accurate in predicting sizing and symmetry, especially in ptotic breasts. To avoid compromising the blood supply of the overlying skin with subcutaneous implants, a vertical inframammary incision was used for the SSM, and at least 5 millimeters of subcutaneous fat was kept with the skin envelope when possible. The decision to place implants subcutaneously versus subpectoral was based on the judgment of the senior author and guided predominately by the viability of the mastectomy skin flaps intraoperatively.

#### Other Complications

The majority of complications were minor and were much lower than quoted in literature. Malrotation of the implant is a recognized complication in literature with a prevalence of 47% in subcutaneously placed implants.<sup>5</sup> Our series reported a prevalence of 11.5%. Subsequent evolution of the surgical technique at our institution involved a more aggressive closure of the lateral pocket with a barb suture to minimize malrotation. Our reported rates of seromas and hematomas were consistent with those reported in literature.<sup>12,22</sup> Seromas and hematomas were all managed with oral antibiotics and/or percutaneous drainage with no long-term sequelae. Subsequent fat injection (for contour defects) was required in 19.2% (n = 5) of patients for hollowing of the upper poles. Our rates of fat grafting were higher than those reported in recent literature of 9–12%.<sup>13,22</sup> This may be explained by the fact that we did not use any mesh or ADM coverage of the implant, which may theoretically make contour defects more pronounced. Nevertheless, all fat grafting cases were managed with day-only procedures with no subsequent complications.

Another key advantage with subcutaneous insertion of the implant, that has also been reported in the literature,

is zero animation deformity and improved patient comfort due to preservation of the pectoralis muscle.<sup>12</sup>

There was no predictive factors for other postoperative complications from our patient cohort. This is in contrast to recent literature, which has reported higher rates of complications in smokers and in older populations.<sup>23</sup>

#### Incision Type

All patients had their implants placed through a vertical infraareolar incision, and this offers a number of advantages. From the mastectomy point of view, there is good access and a comparable surgical view to other incision patterns. A vertical incision theoretically preserves superiorly based axial blood supply and inferiorly based random blood supply as the incision is parallel to the blood vessels. There is a paucity of literature that directly evaluates incision type and blood flow. One study showed a 36% reduction in the superficial circulation as measured by fluorescein flowmetry 2cm below the nipple areolar complex in those patients undergoing a submammary incision versus a “lazy-S” horizontal-shaped lateral incision.<sup>16</sup> The other advantage of our infraareolar vertical incision is that in those with ptotic breasts, a combined mastopexy and implant reconstruction has a better cosmetic outcome and both can be undertaken via the same approach. In this case series, approximately 84.6% (n = 22) of patients had breast ptosis grade 2 or higher preoperatively. In these patients, the practice has been to also resect the nipple as this offers a better cosmetic outcome in terms of breast shape and breast lift and converts a grade 2-, 3-, and 4-breast ptosis into a grade 1-breast ptosis.

Only 1 other study to date has looked at vertical incision in subcutaneously placed implants and they have cited similar benefits. They further described deepithe-



lization rather than excision of the skin along the vertical incision to create a dermal flap, which acts as an extra layer of soft-tissue support for the implant.<sup>13</sup>

### Limitations of Study

This was a retrospective case series from a single institution, which can give rise to selection bias. We did not have any data on patients' body mass index, which can influence the vascularity of the skin flaps, postoperative complications, and can influence the decision to adopt a more traditional submuscular approach or use of ADM if implant visibility and rippling are predictable. In addition, there were a limited number of patients in this study.

Nonetheless, the findings in this study still provide useful insight into the role of subcutaneous placed implants without ADM in the modern surgical era. This the first study of its type to show the feasibility and excellent outcomes of subcutaneous placement of implants without the need for mesh or ADM coverage of the implant. It can be performed on a diverse range of patients including those with larger or ptotic breasts. Additionally, from a cost-effectiveness point of view, our surgical approach is also beneficial. Although we did not undertake a cost analysis, the reduced operating time in a single-stage procedure and from not mobilizing the pectoralis major muscle and the savings from not using a mesh or ADM coverage over the implant is substantial. However, this was offset by the higher rates of fat grafting procedures for contour deformities, but the purpose of this study was not to directly evaluate the cost benefit of the procedure.

Given the feasibility of this approach, we will aim to conduct future prospective studies to evaluate a cost benefit analysis and patient and surgeon assessment of outcomes to directly compare with traditional submuscular single- or 2-stage implant-based reconstruction.

### CONCLUSIONS

SSM with immediate subcutaneous silicon implantation is an acceptable and safe method for breast reconstruction. It offers a number of advantages including ease of dissection for surgeons, improved symmetry, and low complication rates. With improvements in surgical techniques in preserving mastectomy skin flap viability, the use of cohesive silicone gel implants and our vertical inframammary incision, the traditionally higher rates of complications in subcutaneous implants may be outdated.

Apresh Singla, MBBS, MSc  
77 Donovan Avenue  
Maroubra, 2035  
Australia  
Email: apresh.singla@gmail.com

### REFERENCES

1. Agrawal A, Sibbering DM, Courtney CA. Skin sparing mastectomy and immediate breast reconstruction: a review. *Eur J Surg Oncol.* 2013;39:320–8.
2. Benediktsson KP, Perbeck L. Survival in breast cancer after nipple-sparing subcutaneous mastectomy and immediate reconstruction with implants: a prospective trial with 13 years median follow-up in 216 patients. *Eur J Surg Oncol.* 2008;34:143–8.
3. Colwell AS, Damjanovic B, Zahedi B, et al. Retrospective review of 331 consecutive immediate single-stage implant reconstructions with acellular dermal matrix: indications, complications, trends, and costs. *Plast Reconstr Surg.* 2011;128:1170–8.
4. Cassileth L, Kohanzadeh S, Amersi F. One-stage immediate breast reconstruction with implants: a new option for immediate reconstruction. *Ann Plast Surg.* 2012;69:134–8.
5. Al-Ghazal SK, Blamey RW. Subcutaneous mastectomy with implant reconstruction: cosmetic outcome and patient satisfaction. *Eur J Surg Oncol.* 2000;26:137–141.
6. Roostaeian J, Pavone L, Da Lio A, et al. Immediate placement of implants in breast reconstruction: patient selection and outcomes. *Plast Reconstr Surg.* 2011;127:1407–16.
7. Kim JY, Davila AA, Persing S, et al. A meta-analysis of human acellular dermis and submuscular tissue expander breast reconstruction. *Plast Reconstr Surg.* 2012;129:28–41.
8. Gruber RP, Kahn RA, Lash H, et al. Breast reconstruction following mastectomy: a comparison of submuscular and subcutaneous techniques. *Plast Reconstr Surg.* 1981;67:312–17.
9. Schlenker JD, Bueno RA, Ricketson G, et al. Loss of silicone implants after subcutaneous mastectomy and reconstruction. *Plast Reconstr Surg.* 1978;62:853–61.
10. Benediktsson K, Perbeck L. Capsular contracture around saline-filled and textured subcutaneously-placed implants in irradiated and non-irradiated breast cancer patients: five years of monitoring of a prospective trial. *J Plast Reconstr Aesthet Surg.* 2006;59:27–34.
11. Bernini M, Calabrese C, Cecconi L, et al. Subcutaneous direct-to-implant breast reconstruction: surgical, functional, and aesthetic results after long-term follow-up. *Plast Reconstr Surg Glob Open.* 2015;3:e574.
12. Kobraei EM, Cauley R, Gadd M, et al. Avoiding breast animation deformity with pectoralis-sparing subcutaneous direct-to-implant breast reconstruction. *Plast Reconstr Surg Glob Open.* 2016;4:e708.
13. Becker H, Lind JG, 2nd, Hopkins EG. Immediate implant-based prepectoral breast reconstruction using a vertical incision. *Plast Reconstr Surg Glob Open.* 2015;3:e412.
14. Gould DJ, Hunt KK, Liu J, et al. Impact of surgical techniques, biomaterials, and patient variables on rate of nipple necrosis after nipple-sparing mastectomy. *Plast Reconstr Surg.* 2013;132:330e–338e.
15. Maxwell GP, Storm-Dickerson T, Whitworth P, et al. Advances in nipple-sparing mastectomy: oncological safety and incision selection. *Aesthet Surg J.* 2011;31:310–19.
16. Proano E, Perbeck LG. Influence of the site of skin incision on the circulation in the nipple-areola complex after subcutaneous mastectomy in breast cancer. *Scand J Plast Reconstr Surg Hand Surg.* 1996;30:195–200.
17. Rawlani V, Fiuk J, Johnson SA, et al. The effect of incision choice on outcomes of nipple-sparing mastectomy reconstruction. *Can J Plast Surg.* 2011;19:129–33.
18. Jensen JA, Orringer JS, Giuliano AE. Nipple-sparing mastectomy in 99 patients with a mean follow-up of 5 years. *Ann Surg Oncol.* 2011;18:1665–70.
19. Corp I. IBM SPSS Statistics for Windows. 21.0 ed. Armonk, NY: 2012.
20. Al-Ghazal SK, Sully L, Fallowfield L, et al. The psychological impact of immediate rather than delayed breast reconstruction. *Eur J Surg Oncol.* 2000;26:17–19.
21. Elder EE, Brandberg Y, Björklund T, et al. Quality of life and patient satisfaction in breast cancer patients after immediate breast reconstruction: a prospective study. *Breast.* 2005;14:201–8.
22. Wong CH, Samuel M, Tan BK, et al. Capsular contracture in subglandular breast augmentation with textured versus smooth breast implants: a systematic review. *Plast Reconstr Surg.* 2006;118:1224–36.
23. Downs RK, Hedges K. An alternative technique for immediate direct-to-implant breast reconstruction—a case series. *Plast Reconstr Surg Glob Open.* 2016;4:e821.